

Case Study

Ultrasound of Abdomen in Dengue Hemorrhagic Fever: Case Study

Nursama Heru Apriantoro, Puji Supriyono, Halimatus sa'diah, Ade Rochimat

Department of Radiodiagnostic and Radiotherapy, Poltekkes Kemenkes Jakarta II, Jakarta, Indonesia

(Correspondence author's email, nursamaheru@poltekkesjkt2.ac.id / +628996254512)

ABSTRACT

The objective of study to evaluate technical scanning and Image result of dengue haemorrhagic fever (DHF) on abdominal ultrasound examination. The Methods was a case study Presentation from 3 patients, and observations were taken from March 2022 to July 2022 at the RSUD Cengkareng Jakarta. Using a 3.5 MHz frequency convex transducer, take longitudinal and transverse shots with the supine patient position. Scanning focuses on the peritoneal cavity to evaluate the presence of plasma fluid that fills the peritoneal cavities. The results showed that the abdominal ultrasound examination procedure with clinical DHF was well done with patient preparation not eating fibrous at least 4 hours, drinking 3-4 glasses of water and holding urination about 2 hours to fill the bladder. The results show that there is fluid in the peritoneal cavity.

Keywords : Dengue Haemorrhagic Fever, Abdomen Ultrasonography, Peritoneal Cavity Fluid.

<https://doi.org/10.33860/jik.v16i4.2391>



© 2023 by the authors. Submitted for possible open access publication under the terms and conditions of the Creative Commons Attribution (CC BY SA) license (<https://creativecommons.org/licenses/by-sa/4.0/>).

INTRODUCTION

Dengue hemorrhagic fever (DHF) is an infectious disease caused by the dengue virus including the Flavivirus genus of the Flaviviridae family with viral serotypes namely DEN-1, DEN-2, DEN-3, DEN-4¹⁻⁴ which can result in a spectrum of clinical manifestations that vary between the mildest, dengue fever dengue virus (DD), DHF and dengue fever accompanied by scarring or dengue shock syndrome (DSS), transmitted by *Aedes aegypti* and *Ae. mosquito*s. Infected *Albopictus*⁵⁻⁷. The incidence of DHF, due to multiple causes, means that the emergence of pain due to various interacting factors, including agents (dengue virus), vulnerable (human) hosts and the environment that allows the growth and proliferation of *Aedes mosquito*s⁸⁻¹⁰. Besides that, it is also influenced by predisposing factors including population density and mobility, housing quality, distance between homes,

education, employment, life attitudes, age groups, ethnicities, vulnerability to diseases, and others^{11,12}.

In the first degree the patient experiences symptoms such as fever accompanied by other clinical symptoms, without spontaneous bleeding, high body temperature with a cycle of 2-7 days, positive tourniquet laboratory test, thrombocytopenia, hemoconcentration. When there is an increase to degree II, the patient experiences the same symptoms as first degree symptoms, but is added by the presence of spontaneous symptoms such as petechiae, ecchymosis, melena, bleeding in the gums. In grade III the patient experiences symptoms of circulatory failure such as a weak and fast pulse with a size (> 120x / min) narrow pulse pressure with a size (≤ 120 mm Hg), blood pressure decreases with size (120/80 120/100 120 / 110 90 / 70 80/70 80/0 0/0). At the last degree, that is, the degree of the pulse is not palpable, blood pressure is

irregular (heart rate ≥ 140 x / min) the upper limbs and lower limbs are felt cold, sweaty and the skin looks blue.

According to records with clinical DHF at the Cengkareng Regional General Hospital in Jakarta, abdominal ultrasound examinations within a period of one to two months were recorded in around 2-4 patients. An interesting DHF case related to abnormalities in several organs in the abdomen is the discovery of fluid in the peritoneal cavity.

Basically, an ultrasound examination can strengthen the suspicion of the disease if previously accompanied by laboratory tests, to determine whether or not there is a decrease in the number of platelets and leukocytes in the blood. Therefore the main role of ultrasound on examination with clinical DHF is here, as an important addition to adding clinical and laboratory effectiveness in diagnosing dengue fever and to predict the severity of the disease by linking imaging features with platelet counts (13). According to previous research, if it shows an albumin level of <3.5 g / dL, the subjects were positive for dengue fever (DHF) and DHF and had a plasma leak.

Compared with laboratory results and levels, the ultrasound (USG) modalities are very sensitive and specific in visualizing plasma leakage in the form of pleural effusion and / or ascites. Plasma leakage is identified by the presence of pleural effusion and / or ascites with thrombocytopenia^{14,15}. Ultrasound examinations are performed using 3.5 MHz and 5 MHz frequency transducers (16,17). Ultrasound examination of the abdomen is done after 6 hours of fasting to allow for better distension of the gallbladder. In order to be evaluated properly the presence or absence of thickening of the gallbladder wall, which is a definite finding in all positive cases of dengue fever^{14,18-21}.

Abdominal ultrasonography in all subjects was investigated by using 3MHz – 5MHz convex type transducers. Of the 100 research subjects, USG results found the following results: 61.89% had gallbladder walls and bladder wall thickening, 39.44% had ascites, and 61.89% had pleural effusion²². The objective of study to evaluate technical scanning and Image result of dengue haemorrhagic fever (DHF) on abdominal ultrasound examination.

METHOD

This study was case study presentation from 3 patients with clinical indications of DHF from March 2022 to July 2022 at the Cengkareng Regional General Hospital in Jakarta. By conducting an inspection using an aircraft ultrasound Philips HD 15 Pure Wave brand. Transducers used by convex types with a frequency of 3.5 MHz. The technique of moving the transducer is carried out with 4 techniques, namely Pressing, Breathing / Valsalva, Sweeping and Maneuvering.

For the three samples, the same procedure was carried out, namely with the preparation of fasting patients a maximum of 4 hours by holding urination. The position of the research subject is supine on the bed with both hands above the head, the skening is performed with longitudinal and transverse pieces throughout the abdominal organs. For the three samples attaching the number of laboratories in the form of the latest platelets. By looking at the general condition of the three patients the symptoms were different. the first research subjects aged 19 years diagnosed with DHF with 119 thousand / μ L platelet counts came with complaints of shortness of breath, nausea, dizziness, and pain in the joints, especially the lower limbs. The research subjects were examined with supine position on the bed. Skening results obtained in the form of fluid collections in the subhepatic and intrapelvis area and in the liver organs. The second study subjects aged 21 years diagnosed clinically with DHF platelet count 110 thousand / μ L came with complaints of dizziness, nausea and pain joints of lower and upper limbs. Skening results obtained in the form of a picture of minimalfluid colecion at Cul De Sac. patients who are 45 years old with a clinical diagnosis of DHF with a platelet count of 105 thousand / μ L come with complaints of shortness of breath, dizziness and pain in the joints of the lower limbs. The results of skening are obtained in the form of extra pleural effusion.

RESULTS

Based on observations made during observations at the Cengkareng Jakarta General Hospital For patients with Dengue Haemorrhagic Fever indications an examination was carried out in the entire abdominal organs, but more

focused on areas susceptible to abnormalities such as the Hepatorenal, Spleenorenal, Cul de sac and biological organs. bile.

The following are the pathology results obtained from the three samples with clinical dengue haemorrhagic fever. The ultrasound results in clinical DHF are shown in Figures 1, 2, 3 and Figure 4.

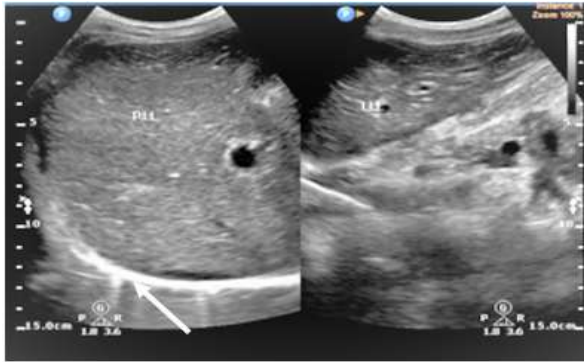


Figure 1. The patient's first ultrasound results with indications of Acites Pleural Dextra.

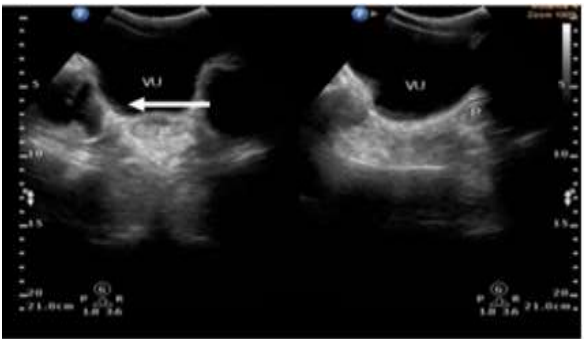
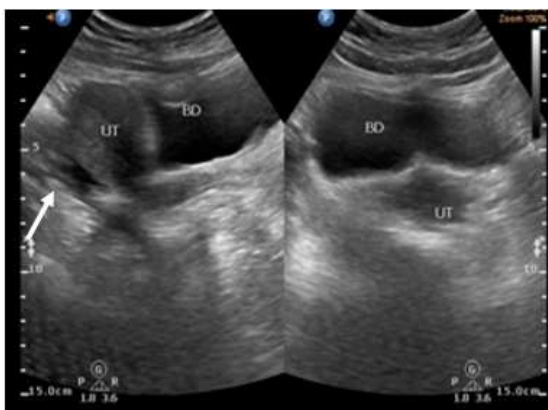


Figure 2. First patient USG results with indications of subhepatic and intra pelvis fluid collection.

In the first patient on the results of the longitudinal skening shown in Figure 1 on the liver, a mirror image was shown firmly on the posterior image, a homogeneous parenchymal



texture with an increase in echo with a hyperechoic appearance, the anterior wall in the liver was not bounded with anechoic edge.

Figure 3. The patient's second ultrasound with a minimum fluid collection at Cul De Sac.

The vascular system does not widen. Then on other organs The results of the bladder sketch shown in Figure 2 show a picture of a fully filled bladder with anechoic images with a regular wall, showing images of anechoic in subhepatic and intra pelvis. no picture of acoustic shadowing, no picture of an enlarged bladder.

In the second patient on the results of bladder scanning shown in Figure 3, there is a picture of a jar that is not too full, a regular wall, and anechoic picture on the cul de sac. no picture of Acoustic shadowing, no picture of an enlarged bladder.

In the third patient on the results of the longitudinal scanning in the liver shown in Figure 4, an anechoic picture outside the diaphragm was seen, an increase in echogenicity in the form of a hyperechoic image, the structure of the liver parenchyma appeared homogeneous with port veins and branches as a regular, tubular structure. There is no visible widening of the vascular system nodule.

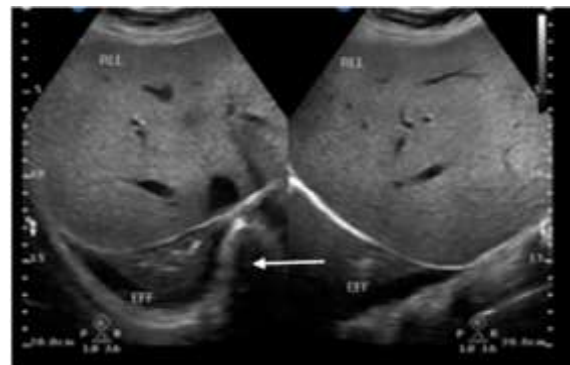


Figure 4. The ultrasound results of research subjects 3 with a description of dextra pleural effusion.

DISCUSSION

The ultrasound procedure performed is correct, the results of abdominal ultrasound in clinical DHF are not only subjects with platelets below 100 thousand / μ L who

experience plasma seepage depending on the antibody of the study subjects, but in the study subjects with platelet counts above 100 thousand / μL also allows for plasma seepage in the peritoneal cavity. Therefore abdominal ultrasound examination in the entire organ carefully and must attach the latest laboratory results to strengthen the diagnosis of DHF

Based on observations made during the observation at Cengkareng General Hospital Jakarta, for patients with indications of Dengue Hemorrhagic Fever, examination of all abdominal organs is carried out, but more focused on areas that are prone to abnormalities such as Hepatorenal, Splenorenal, Cul de sac and Biological. The pathological results were obtained from the three samples with clinical dengue hemorrhagic fever. Ultrasound results in clinical DHF are shown in Figures 1, 2, 3, and 4. In the first patient on the longitudinal scan results shown in Figure 1 of the liver, the mirror image is clearly shown on the posterior image, parenchymal texture is homogeneous with increased echo with a hyperechoic appearance, the anterior wall of the liver is not bounded by the anechoic rim. no Acoustic shadowing images, no enlarged bladder images. In the second patient, the results of the bladder scan are shown in Figure 3, there is a not too full jar, a regular wall, and an anechoic appearance on the cul de sac. no Acoustic shadowing images, no enlarged bladder images. In the third patient, the results of a longitudinal scan of the liver seen in Figure 4 show an anekonic appearance outside the diaphragm, increased echogenicity in the form of a hyperechoic appearance, the structure of the liver parenchyma looks homogeneous with port veins and branches as ordinary tubular structures. strengthen the diagnosis of DHF.

CONCLUSION

The ultrasound procedure that was carried out was correct. The results of abdominal ultrasound in clinical DHF were not only in subjects with platelets below 100 thousand/ μL who experienced plasma seepage depending on the study subject's antibodies but in study subjects with platelet counts above 100 thousand/ μL it was also possible for seepage to occur. plasma in the peritoneal cavity.

ACKNOWLEDGMENTS

We would like to thank the Director of Radiodiagnostic and Radiotherapy Department of Politeknik Kesehatan Kementerian Kesehatan Jakarta II, Ministry of Health for his contributions during the study. We are sincerely grateful to the Directors, Sonographers and District General Hospital of Cengkareng Jakarta staff for their valuable contributions, facilities, assistance and constructive suggestions during our study.

CONFLICTS OF INTEREST

The authors affirm no conflict of interest in this study.

REFERENCE

1. WHO. Handbook for clinical management of dengue. Geneva: WHO. 2012.
2. Tjioenata MM, Lukas S, Stefani D, Widjaja P. Analysis of The Sirs Model Of The Spread of Dengue Hemorrhagic Fever Using Runge-Kutta Method and Genetic Algorithm. *J Inf Syst Dev*. 2023;8(1):43–7.
3. Mariko R, Darwin E, Yanwirasti Y, Hadinegoro SR. The difference of sve-cadherin levels between dengue hemorrhagic fever patients with shock and without shock. *Open Access Maced J Med Sci*. 2019;7(14):2277–81.
4. Jamil Z, Farooq U, Kazmi S. Dengue Hemorrhagic Fever. *J Akhtar Saeed Med Dent Coll*. 2022;04(02):87–9.
5. Supartha IW. Pengendalian Terpadu Vektor Virus Demam Berdarah Dengue, *Aedes aegypti* (Linn.) dan *Aedes albopictus* (Skuse) (Diptera: Culicidae). *Pertem Ilm Univ Udayana*. 2008;(September):3–6.
6. Setiawan AR, Fadila SZ, Sucipto TH, Fauziyah S, Madaniyah S, Dewi EC, et al. Detection of homozygous wildtype V1016V using allele-specific polymerase chain reaction in *Aedes albopictus*. *Biodiversitas*. 2023;24(1):62–7.
7. Martini M, Armen Z, Nissa K, Retno H, Sri Y, Atik M, et al. Entomological Status Based on Vector Density Index and Transovarial Infection on *Aedes* Sp. Mosquito in Meteseh Village, Semarang City. *E3S Web Conf*. 2020;202.
8. Kasjono H KH. *Intisari Epidemiologi*. Mitra Cendikia Press, editor. Jakarta; 2008.
9. Batool K, Alam I, Liu P, Shu Z, Zhao S, Yang W, et al. Recombinant Mosquito Densovirus with Bti Toxins Significantly

- Improves Pathogenicity against *Aedes albopictus*. *Toxins (Basel)*. 2022;14(2):1–15.
10. Wilke ABB, Vasquez C, Carvajal A, Moreno M, Fuller DO, Cardenas G, et al. Urbanization favors the proliferation of *Aedes aegypti* and *Culex quinquefasciatus* in urban areas of Miami-Dade County, Florida. *Sci Rep [Internet]*. 2021;11(1):1–12. Available from: <https://doi.org/10.1038/s41598-021-02061-0>
 11. Sari CIN. Pengaruh Lingkungan Terhadap Perkembangan Penyakit Malaria Dan Demam Berdarah Dengue. IPB, editor. Bogor; 2005.
 12. Oroh MY, Pinontoan OR, Tuda JBS. Faktor Lingkungan, Manusia dan Pelayanan Kesehatan yang Berhubungan dengan Kejadian Demam Berdarah Dengue. *Indones J Public Heal Community Med*. 2020;1(3):35–46.
 13. Santhosh VR, Patil PG, Srinath MG, Kumar A, Jain A, Archana M. Sonography in the diagnosis and assessment of dengue Fever. *J Clin Imaging Sci*. 2014;4(1):14.
 14. Moras E, Achappa B, Murlimanju B V., Raj GMN, Holla R, Madi D, et al. Early diagnostic markers in predicting the severity of dengue disease. *3 Biotech [Internet]*. 2022;12(10):1–9. Available from: <https://doi.org/10.1007/s13205-022-03334-9>
 15. Pathak B, Chakravarty A, Krishnan A. High viral load positively correlates with thrombocytopenia and elevated haematocrit in dengue infected paediatric patients. *J Infect Public Health [Internet]*. 2021;14(11):1701–7. Available from: <https://doi.org/10.1016/j.jiph.2021.10.002>
 16. Singh DK. Assessment of Gall Bladder. 2023;424–7.
 17. Abdelmofeed A, Awaad M, Atef F. Role of Ultrasonography in Gall bladder Dyskinesia as a cause of Functional Dyspepsia Symptoms. *Benha Med J*. 2021;0(0):0–0.
 18. Pratomo IP, Yunus F, Pulmonologi D, Respirasi K, Kedokteran F, Indonesia U. Anatomi dan Fisiologi Pleura. *Contin Med Educ*. 2013;40(6):407–12.
 19. Sudarsih, Kesawa;Setia Budi W. Analisis Keseragaman Citra Pada Pesawat Ultrasonografi. 2014;17(1):33–8.
 20. Kurniawan A, Rahmat, Kartapraja RD. Journal of Innovation Research and Knowledge. *J Innov Res Knowl*. 2023;2(11):4315–24.
 21. Gleeson T, Pagnarith Y, Habsreng E, Lindsay R, Hill M, Sanseverino A, et al. Dengue Management in Triage using Ultrasound in children from Cambodia: a prospective cohort study. *Lancet Reg Heal - West Pacific [Internet]*. 2022;19:100371. Available from: <https://doi.org/10.1016/j.lanwpc.2021.100371>
 22. Nida Sha , Rehana Mushtaq FB. Pakistan biomedical journal. 2021;(c):37–40.